

·临床研究·

## 腰椎间隙感染肺炎克雷伯菌合并阴沟肠杆菌的诊疗

程翰文<sup>1</sup>, 吴朝娟<sup>2</sup>, 刘卓劼<sup>1</sup>, 吴昊宇<sup>1</sup>, 张 笛<sup>1</sup>, 王 宁<sup>1</sup>, 李春海<sup>1,3</sup>

(1. 中山大学孙逸仙纪念医院骨外科, 广东 广州 510120; 2. 西南医科大学临床医学院, 四川 泸州 646000; 3. 中山大学孙逸仙纪念医院外科教研室 广东 广州 510120)

**摘要:**【目的】罕见的原发性腰椎间隙感染肺炎克雷伯菌合并阴沟肠杆菌的临床诊疗初探, 为此类罕见脊柱感染诊疗提供临床经验。【方法】腰痛伴左下肢麻木7月余、加重1周余的老年男性患者, 经实验室、影像学检查, 诊断为腰椎间盘突出症, 入院后症状急性加重, 复查腰椎增强MRI示L3/4椎间隙后部局部强化信号, VAS评分9分, 腰部JOA评分6分。实施腰椎后路L3/4、L4/5椎间盘摘除+cage植骨融合+L3-L5椎弓根钉棒内固定术, 并留取术中L3/4椎间盘标本备细菌培养。【结果】细菌培养结果回示肺炎克雷伯杆菌及阴沟肠杆菌感染, 术后敏感抗生素治疗6周, 患者在术后半年的随访中获得痊愈。【结论】对临床表现为急性剧烈腰痛或下肢疼痛的中老年患者, 在常规实验室、影像学检查提示腰椎退行性疾病的同时应考虑脊柱感染可能。

**关键词:** 腰椎间隙感染; 肺炎克雷伯菌; 阴沟肠杆菌; 鉴别诊断

中图分类号: R681.5; R378 文献标志码: D 文章编号: 1672-3554(2023)03-0485-05

DOI: 10.13471/j.cnki.j.sun.yat-sen.univ(med.sci).2023.0316

## Diagnosis and Treatment of Klebsiella Pneumoniae Combined with Enterobacter Cloacae in Lumbar Intervertebral Space Infection

CHENG Han-wen<sup>1</sup>, WU Zhao-juan<sup>2</sup>, LIU Zhuo-jie<sup>1</sup>, WU Hao-yu<sup>1</sup>, ZHANG Di<sup>1</sup>,  
WANG Ning<sup>1</sup>, LI Chun-hai<sup>1,3</sup>

(1. Department of Orthopedic Surgery, Sun Yat-sen Memorial Hospital, Sun Yat-sen University, Guangzhou 510120, China; 2. School of Clinical Medicine, Southwest Medical University, Luzhou 646000, China; 3. Department of Surgery, Sun Yat-sen Memorial Hospital, Sun Yat-sen University, Guangzhou 510120, China)

Correspondence to: LI Chun-hai; E-mail: lichhai@mail.sysu.edu.cn

**Abstract:**【Objective】To explore the clinical diagnosis and treatment of rare primary lumbar intervertebral space infection with Klebsiella pneumoniae and Enterobacter cloacae, and provide clinical experience for the diagnosis and treatment of this rare spinal infection.【Methods】An elderly male patient with low back pain and numbness in the left lower extremity for more than 7 months, which aggravated for more than 1 week, was diagnosed with lumbar disc herniation after laboratory and imaging examinations. After admission, the symptoms became acutely aggravated, and re-examination of lumbar enhanced MRI showed local enhancement at the posterior edge of the L3/4 intervertebral space. The VAS score was 9 points, and the lumbar JOA score was 6 points. A posterior lumbar interbody fusion of L3-L5 was performed, and L3/4 intervertebral disc specimens were collected during the operation for bacterial culture.【Results】Bacterial culture results showed Klebsiella pneumoniae and Enterobacter cloacae infection. The patient was treated with sensitive antibiotics for 6 weeks after the operation, and the patient was cured during the follow-up of half a year after the operation.【Conclusion】For middle-aged and elderly patients with clinical manifestations of acute severe low back pain or lower extremity pain, the possibility of spinal infection should be considered when routine laboratory and imaging examinations suggest lumbar degenerative diseases.

收稿日期: 2022-10-31

基金项目: 广州市科技计划项目(202102010259)

作者简介: 程翰文, 硕士生, 研究方向: 脊柱外科, E-mail: chenghanwen1998@126.com; 李春海, 通信作者, 主任医师, 硕士生导师, E-mail: lichhai@mail.sysu.edu.cn

**Key words:** infection of lumbar intervertebral space; Klebsiella pneumoniae; enterobacter cloacae; differential diagnosis

[J SUN Yat-sen Univ(Med Sci), 2023, 44(3): 485-489]

肺炎克雷伯菌、阴沟肠杆菌是重要的条件病原菌<sup>[1]</sup>,在宿主免疫功能低下、菌群失调时可以造成人体多部位感染,甚至引起毒血症<sup>[2]</sup>。迄今为止,国内外有关报道腰椎间隙感染肺炎克雷伯菌或阴沟肠杆菌的临床案例尚属罕见<sup>[3]</sup>。肺炎克雷伯菌结合阴沟肠杆菌引起腰椎间隙感染的症状和影像学特征并无特殊,常与位于腰椎的肿瘤、结核、或其他非特异性的感染性疾病相混淆,从而造成早期漏诊、误诊。本院2022年5月14日收治腰椎间隙肺炎克雷伯菌结合阴沟肠杆菌感染病人一例,报道如下。

## 1 材料与方法

### 1.1 一般资料

患者,男,66岁,高级通信工程师,主因“腰痛伴左下肢麻木7月余、加重1周余”入院。入院前7个月在藏区长期跋涉、工作后出现腰痛伴左下肢麻木。本次入院6个月前曾于我院就诊,腰椎磁共振成像(magnetic resonance imaging, MRI)示“L3/4、L4/5腰椎间盘突出”,行保守治疗,患者不适稍缓解,无发热,无剧烈疼痛。一周余前劳累后出现腰痛伴左下肢持续针刺样疼痛,疼痛剧烈,未见盗汗及发热, MRI示“L3/4、L4/5椎间盘突出”,考虑腰椎间盘突出症加重,返院治疗。本研究获得中山大学孙逸仙纪念医院医学伦理委员会批准(伦理审批号:SYSKY-2022-199-01),患者签署知情同意后纳入本研究。

体格检查:体温:36.5℃,脉搏:85次/分,呼吸:20次/分,血压:147/87 mmHg。患者跛行步态,脊柱活动度受限。腰4/5棘突、棘间及棘旁有轻压痛,腰4/5棘间、棘旁叩击痛阳性,左侧小腿前外侧及足背感觉减退,伸膝肌力下降,左伸膝肌、左踝背屈肌、左踝跖屈肌、左膝背屈肌、左膝跖屈肌肌力为4级,其余正常。左侧直腿抬高试验30°阳性,加强试验阳性,病理征阴性。视觉模拟评分法(Visual Analogue Scale, VAS)评分8分,腰椎日本骨科协会评估治疗分数(Japanese Orthopaedic Association Scores, JOA)评分7分。

### 1.2 实验室检查

实验室检查:红细胞沉降率(erythrocyte sedimentation rate, ESR)12.0 mm/h(0.0~15.0 mm/h);降钙素原<0.05(0~0.1 ng/mL);C反应蛋白(C-reactive protein, CRP)<3.3 mg/L(<5 mg/L);超敏C反应蛋白(hypersensitive-C-reactive-protein, hs-CRP)2.54 mg/L(0.00~3.00 mg/L);白细胞 $7.79 \times 10^9/L$ ( $3.50 \times 10^9/L \sim 9.50 \times 10^9/L$ );血培养7 d厌氧菌、细菌、真菌培养阴性;鳞状上皮细胞癌抗原1.62 ng/mL( $\leq 2.7$  ng/mL);细胞角蛋白19片段1.69 ng/mL( $\leq 3.3$  ng/mL);神经元特异性烯醇化酶13.9 ng/mL( $\leq 16.3$  ng/mL);糖类蛋白等肿瘤系列标记物阴性。

### 1.3 影像学检查

腰椎正侧位X线片见椎体形态良好,椎间隙无狭窄。腰椎CT未见骨质破坏,仅椎间盘退行性改变。腰椎MRI提示L3/4椎间盘向后突出,L4/5椎间盘向后膨出,局部硬膜囊和椎间孔受压明显,椎间盘退行性改变,未见肿瘤和感染征象。

### 1.4 诊断及鉴别诊断

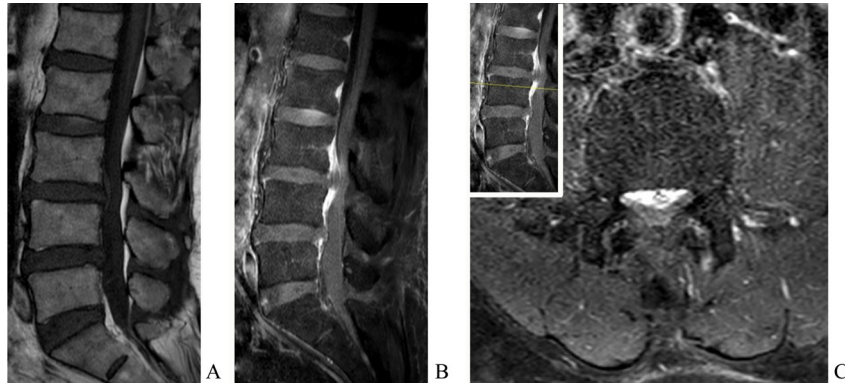
根据本例患者病史、影像学及实验室检查结果,经专业组及科室讨论得出初步诊断:腰间盘突出症(L3/4、L4/5伴左侧神经根病)可能性大。诊断要点如下:①老年男性,慢性病程,急性加重。②无发热病史,ESR、CRP未见明显升高,血培养相关结果阴性。③影像学未见骨破坏、椎间隙狭窄、软组织侵犯。④肿瘤系列相关实验室检查阴性。

鉴别诊断主要考虑以下几个方面:①软组织损伤:肌肉、筋膜或韧带的损伤可导致较广泛的腰背部疼痛,影像学无特异表现。②脊柱细菌性感染:患者多疼痛剧烈,活动明显受限,CRP及ESR升高,抗结核治疗无效,有时可见全身症状。③腰椎结核感染:往往有低热盗汗等临床症状,有肺结核病史或高危流行病学接触史,影像学有冷脓肿形成、严重骨破坏等征象。④脊柱肿瘤:患者有脊背部剧烈疼痛、夜间痛并出现感觉异常,合并出现其他系统的症状<sup>[4]</sup>。

### 1.5 治疗过程

患者在院等待择期手术治疗期间,发生腰痛伴左下肢疼痛症状急性加重,强迫体位,不能翻身,不

可下床行走, VAS(9分), 腰椎JOA(6分)。查体: 双下肢肌力Ⅲ-Ⅳ级, 双侧Babinski's sign(-), 腱反射减退。复查腰椎增强MRI提示: L3/4椎间盘向后脱出, 增强后局部明显强化(图1B、C)。考虑患者有腰椎感染可能性, 于2022-05-24全麻下行腰椎后路L3/4、L4/5椎间盘摘除+cage植骨融合+L3-L5椎弓根钉棒内固定术, 并取L3/4椎间隙组织样本送检。



A: Lumbar spine MRI showed that L3/L4 intervertebral disc herniation, when the patient was admitted to the hospital; B-C: After the patient's symptoms worsen, enhanced MRI showed that L3/4 intervertebral disc herniation, and local enhancement.

图1 患者的腰椎MRI与腰椎增强MRI不同影像学表现

Fig. 1 Different imaging manifestations between lumbar spine MRI and lumbar spine enhanced MRI in this case

术后7 d培养结果回示:肺炎克雷伯杆菌及阴沟肠杆菌感染。病理结果回示:镜下所见L3/4椎间盘、L4/5椎间盘髓核组织,未见明显感染或肿瘤异常征象(图2A、B)。术后常规使用头孢呋辛钠1.5 g每天静脉滴注(intravenous, iv)预防感染,术后第一天体温37.3℃。根据细菌培养及药敏试验结果结合药学部建议,以舒普深3 g每8 h静脉注射治疗26 d。经过手术及敏感抗生素治疗后,患者强迫体位解除,疼痛症状消失,麻木症状较前缓解,恢复正常步态, VAS(1分), 腰椎JOA(26分)四肢肌力正常, 腱反射恢复正常。出院后考虑患者治疗便利性,舒普深3 g每8 h静脉注射更改治疗计划为阿米卡星0.6 g每天静脉注射共14 d,达到6周抗生素治疗疗程。出院时患者一般情况良好,未见明显感染症状。

术后1个月随访,患者疼痛消失,复查CRP、ESR正常,复查X线片示腰椎内固定在位,未见明显松脱。术后3个月随访,患者无腰部疼痛,复查CRP、ESR正常,复查腰椎MRI增强示L3-L5病灶基本吸收,局部无异常增强信号,椎管内无占位(图2C、D)。

## 2 结果

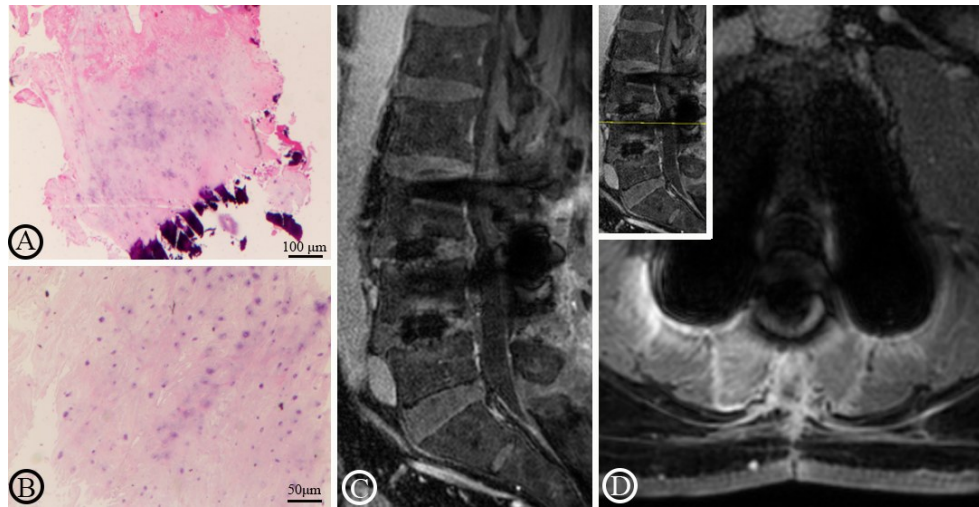
对比患者入院时腰椎MRI(图1A),患者症状急性加重后复查的增强MRI发现:除外椎间盘突出征象,可见L3/4后缘局部明显强化,提示局部炎症、感染可能(图1B、C)。

## 3 讨论

### 3.1 病原学

原发性脊柱感染以细菌感染为主,尤其以慢性低毒力性细菌感染多见<sup>[5-6]</sup>。肺炎克雷伯菌是临床分离常见的革兰阴性杆菌,一种存在于人体肠道、胆道、呼吸道、泌尿生殖道的条件致病菌,可引起新生儿化脓性关节炎<sup>[7]</sup>、肝脓肿<sup>[8]</sup>、脓毒性肺栓塞<sup>[9]</sup>和脑膜炎<sup>[10]</sup>等多种疾病。阴沟肠杆菌是肠杆菌属中的一种,常存在于土壤、污水、健康人及动物的胃肠道,是一种机会致病菌,可引起颈椎间盘炎<sup>[11]</sup>、心内膜炎<sup>[12]</sup>、肩部脓毒性单关节炎<sup>[13]</sup>、败血症等疾病。肺炎克雷伯菌可通过抗吞噬并抑制ROS生成、抑制NET生成、干扰中性粒细胞凋亡和胞葬来逃避中性粒细胞免疫<sup>[14]</sup>,此例患者术中未见病灶部位脓液形成可能与此机制相关。本例患者长年工作于藏区,生活卫生条件较差,加之过度劳累,年龄较大,给予机会性致病菌定植机会。

本例患者入院后的血培养结果为阴性,实验室检验结果提示感染相关指标皆在正常值范围,极易导致临床医师的误诊,但是这种现象在Dai等<sup>[15]</sup>的队列研究中被证实,患者入院时实验室感染相关



A~B: Pathological examination showed no signs of infection or tumor in the nucleus pulposus tissue of the intervertebral disc submitted for examination; C~D: Lumbar spine enhanced MRI of the third month follow-up showed that L3/L4 lesions were absorbed, and there was no abnormal signal.

图2 L3/4病灶组织病理切片与术后复查腰椎增强MRI

Fig. 2 Pathological section of L3/4 tissue and postoperative review of lumbar spine enhanced MRI

指标较低与培养结果阴性密切相关。除此以外,在一些国内外近期研究及指南中也有阐述,脊柱感染血培养阴性并不少见,对怀疑感染者,需要进一步病灶组织活检或其他特异性检测<sup>[16-17]</sup>。入院时培养结果阴性,可能是定值细菌未在血液达到血培养检出浓度,这也与实验室炎症相关指标在正常值范围相印证,而在后续病灶病本培养中,最终检出了肺炎克雷伯及阴沟肠杆菌。

### 3.2 临床表现

本例患者入院时虽有腰痛、活动受限,但无明显发热及流行病学史,实验室相关检查亦为阴性,拟作为常规腰椎间盘突出症治疗时,患者症状再次急性加重,初步诊断存疑。考虑到椎间隙感染多由细菌血行播散引起<sup>[18]</sup>,追问病史,患者自述曾被鱼刺划伤上消化道而出血,推测异物损伤食管血管,机会性致病菌由此入血,而密闭的椎间盘为细菌提供一个潜在的免疫豁免环境<sup>[19]</sup>,髓核血供较差,加之感染的慢性低毒力细菌有一定的免疫逃避能力,导致病原体难以被免疫系统识别。因此感染早期少有全身症状,常规实验室检查也难以有阳性发现。出现疼痛急剧加重的原因一方面可能是椎间盘突出所引起的反射性腰痛,另一方面考虑纤维环逐渐破碎过程中椎间盘内容物不断流出,尤其是炎性介质大量涌入硬膜外隙,局部聚集的高浓度炎性介质刺激神经可导致疼痛症状急性加重。

### 3.3 影像学表现

针对此类脊柱感染,X线和CT的敏感性和特异性不高,这可能会导致早期诊断的延迟<sup>[20]</sup>。MRI可在X线无任何改变前显示椎间隙及椎体信号的改变,是目前脊柱感染最佳的早期检查手段。本病例因入院时MR平扫未发现椎间盘、椎体信号改变,无感染征象,因此开始误诊为椎间盘突出症。在患者症状急性加重后复查的增强MR影像发现:除外椎间盘突出征象,可见L3/4后缘局部明显强化,提示局部炎症、感染可能。

### 3.4 治疗方案

脊柱感染患者在明确病原学证据后,内科治疗首选敏感抗生素静脉滴注至少6周<sup>[16]</sup>。对于有脊髓压迫症状的患者,则需要手术治疗及术后敏感抗生素治疗6~8周<sup>[16]</sup>。本例患者通过手术治疗+舒普深3g每8h静脉注射共26d+阿米卡星0.6g每天静脉注射共14d后,获得神经、肌肉功能的完全恢复。

### 3.5 结论

这个病例提示:对临床表现为急性剧烈腰痛或下肢疼痛的中老年患者,早期常规实验室检查未发现感染征象,在考虑常见的腰椎退行性疾病的同时不要忽略脊柱感染的可能,采取手术治疗的患者应留取病灶标本用以细菌培养明确诊断,防止漏诊、误诊。

## 参考文献

- [1] Brooks CA, Mahajan S, Beresford R, et al. Thoracic spondylodiscitis secondary to *Klebsiella oxytoca* urosepsis—a case report [J]. *J Spine Surg*, 2022, 8 (1): 54–61.
- [2] Ikeda M, Mizoguchi M, Oshida Y, et al. Clinical and microbiological characteristics and occurrence of *Klebsiella pneumoniae* infection in Japan [J]. *Int J Gen Med*, 2018, 11: 293–299.
- [3] 万超, 谢炜星, 晋大祥. 腰椎肺炎克雷伯菌感染1例报告 [J]. *中国脊柱脊髓杂志*, 2016, 26 (6): 568–570.  
Wan C, Xie WX, Jin DX, et al. The infection of the lumbar vertebrae with *Klebsiella pneumoniae*: a case report [J]. *Chin J Spine Spinal Cord*, 2016, 26 (6): 568–570.
- [4] Suratwala SJ, Kondra K, Cronin M, et al. Malignant peripheral nerve sheath tumor of the sciatic nerve presenting with leg pain in the setting of lumbar scoliosis and spinal stenosis [J]. *Spine Deform*, 2020, 8 (2): 333–338.
- [5] Duarte RM, Vaccaro AR. Spinal infection: state of the art and management algorithm [J]. *Eur Spine J*, 2013, 22(12): 2787–2799.
- [6] 郑兴平, 赵俊华, 钟建. 34例腰椎间隙感染的诊断与治疗分析 [J]. *重庆医学*, 2012, 41 (25): 2586–2588.  
Zheng XP, Zhao JH, Zhong J. Analysis on diagnosis and treatment in 34 case of lumbar intervertebral space infection [J]. *Chongqing Medicine*, 2012, 41 (25): 2586–2588.
- [7] Ozsari T, Bora G, Ozdemir OM, et al. A neonatal septic arthritis case caused by *Klebsiella pneumoniae*: A case report [J]. *J Clin Diagn Res*, 2016, 10 (2): SD01–02.
- [8] Premathilake PNS, Kularatne WKS, Jayathilake JPK, et al. *Klebsiella pneumoniae* liver abscess: a case report [J]. *J Med Case Rep*, 2018, 12(1): 367.
- [9] Ojeda Gómez JSA, Carrillo Bayona JA, Morales Cifuentes LC. Septic pulmonary embolism secondary to *Klebsiella pneumoniae* Epididymitis: Case report and literature review [J]. *Case Rep Radiol*, 2019; 2019: 5395090. doi:10.1155/2019/5395090.
- [10] Zhao J, Huo T, Luo X, et al. *Klebsiella pneumoniae*-related brain abscess and meningitis in adults: Case report [J]. *Medicine (Baltimore)*, 2022, 101 (2): e28415.
- [11] 孟飞, 张迪, 张计成, 等. 阴沟肠杆菌引起的原发性颈椎间盘炎一例 [J]. *中华临床感染病杂志*, 2015, 8 (2): 167–169.  
Meng F, Zhang D, Zhang JC, et al. Primary cervical discitis caused by *Enterobacter cloacae*: report of one case [J]. *Chin J Clin Infect Dis*, 2015, 8 (2): 167–169.
- [12] Wengrofsky P, Soleiman A, Benyaminov F, et al. *Enterobacter cloacae* device endocarditis: case report, scoping study, and guidelines review [J]. *Cardiol Vasc Res (Wilmington)*, 2019, 3(3).doi: 10.33425/2639–8486.1050.
- [13] Huang J, Xu Q, Liu F, et al. *Enterobacter cloacae* infection of the shoulder in a 52-year-old woman without apparent predisposing risk factor: a case report and literature review [J]. *BMC Infect Dis*, 2021, 21 (1): 13.
- [14] 王蕾蕾, 王明贵, 杨帆. 肺炎克雷伯菌逃避中性粒细胞免疫的机制 [J]. *中国感染与化疗杂志*, 2022, 22 (2): 241–243.  
Wang LL, Wang ML, Yang F. Potential mechanism underlying *Klebsiella pneumoniae* escaping neutrophils defense [J]. *Chin J Infect Chemother*, 2022, 22 (2): 241–243.
- [15] Dai G, Li S, Yin C, et al. Culture-negative versus culture-positive in pyogenic spondylitis and analysis of risk factors for relapse [J]. *Br J Neurosurg*, 2021; 1–5.
- [16] Berbari EF, Kanj SS, Kowalski TJ, et al. 2015 Infectious Diseases Society of America (IDSA) clinical practice guidelines for the diagnosis and treatment of native vertebral osteomyelitis in adults [J]. *Clin Infect Dis*, 2015; 61(6): e26–e46.
- [17] 于峥嵘, 李淳德, 施学东, 等. 成人原发性脊柱非特异性感染的诊断和治疗 [J]. *中华外科杂志*, 2011 (11): 1054–1055.  
Yu ZR, Li CD, Shi XD, et al. Diagnosis and treatment of primary spinal nonspecific infection in adults [J]. *Chin J Surg*, 2011(11): 1054–1055.
- [18] 朱小龙, 徐卫星, 刘杰. 椎间隙感染的诊断与治疗进展 [J]. *中国骨伤*, 2016, 29(9): 870–874.  
Zhu XL, Xu WX, Liu J. Advances in diagnosis and treatment of intervertebral space infection [J]. *J Chin Orthop Traumatol*, 2016, 29(9): 870–874.
- [19] 陶帅, 姜宏, 王铠, 等. 破裂型与未破裂型椎间盘突出组织超微结构对比观察 [J]. *临床骨科杂志*, 2014, 17(5): 604–607.  
Tao S, Jiang H, Wang K, et al. Ruptured and unruptured comparative study of lumbar disc tissue ultrastructure [J]. *Journal of Clinical Orthopaedics* 用简写, 2014, 17(5): 604–607.
- [20] Torres C, Zakhari N. Imaging of spine infection [J]. *Semin Roentgenol*, 2017, 52(1): 17–26.